



M-Sphere[®]

O R B I T A L I M P L A N T S U R G E R Y

A Step by Step Guide to the Insertion of the Molteno[®] M-Sphere[®]
Natural Hydroxyapatite Orbital Implant

Anthony C. B. Molteno, FRCS, FRACO

Copyright © Anthony C. B. Molteno 1997

M-Sphere®

Cancellous Bone Orbital Implant

The M-Sphere® orbital implant is manufactured from MoaBone®, the natural hydroxyapatite mineral matrix of cancellous bone. The bone, of New Zealand origin, is treated to remove the organic components leaving only the hydroxyapatite mineral framework. M-Sphere® orbital implants are designed to support and impart movement to an artificial eye (prosthesis) after enucleation. Like the mineral portion of human bone, the bony trabeculae within the M-Sphere® provide a completely porous structure which is easily and rapidly incorporated into the tissues.

With careful surgical technique it is possible to insert a relatively large M-Sphere® into Tenon's space and eliminate dead space in the socket. Cosmetically this is highly desirable as it produces a visible bulge behind closed lids giving an impression of a normal closed eye when a artificial eye is not being worn. Furthermore, the movement of the conjunctiva covered orbital implant against the tarsal conjunctiva prevents the accumulation of secretions and maintains a healthy socket. Where customised artificial eyes are not available, a smaller M-Sphere® orbital implant can be used with a stock artificial eye.

In most patients where the tissue is healthy it is not necessary to cover the M-Sphere® with a cap of sclera. However if the tissues are deficient, unduly thin or scarred, donor sclera can be placed over the front of the M-Sphere®.

Features of the M-Sphere® natural hydroxyapatite orbital implant:

- The M-Sphere® is made from MoaBone®, the hydroxyapatite mineral matrix of mammalian cancellous bone. Its natural chemical composition and the preservation of its natural porous structure gives the M-Sphere® full biocompatibility.
- The M-Sphere® is completely porous. When buried in the patient's tissues it is rapidly organised by host fibrovascular tissue.
- When incorporated in the patient's tissue the M-Sphere® resists migration and extrusion. It provides a robust, permanent and mobile support for an artificial eye.
- When fitted with an artificial eye the M-Sphere® gives an excellent cosmetic appearance without the need for drilling and pegging.
- The M-Sphere® is supplied as 16mm, 18mm, 20mm, and 22mm diameter spheres. This allows the correct size of M-Sphere® to be selected to suit the individual case.

Introduction

The orbit is a closed cavity. Complications that arise after inserting an orbital implant are most often due to internal or external pressure.

Internal pressure from the swelling of traumatised tissues or the selection of too large an implant may result in exposure of the implant. External pressure applied to the eye after surgery, such as the use of a conformer or over-firm bandaging, may cause ischaemic necrosis of the tissues covering the implant and should be avoided.

The following steps can be taken to ensure the best results.

1. Selecting the correct size M-Sphere®.

The correct size M-Sphere® is usually about three-quarters the diameter of the eye that has been removed. However, if there are complicating factors such as poor blood supply or badly damaged tissues, a smaller M-Sphere® should be selected.

For example; a 24mm diameter eye has been enucleated. Normally a 20mm M-Sphere® would be considered. However, if the tissues are badly damaged or the patient is old, has vascular disease or there are other factors limiting the vitality of the tissues, or 18mm M-Sphere® should be used.

2. Reducing tissue swelling.

Swelling of the orbital tissues may be present before the enucleation, for example, following trauma. Swelling may also occur in response to manipulation of the tissues during the operation. In either case swelling may be reduced or prevented by administering a non-steroidal anti-inflammatory agent by mouth (with the usual precautions) immediately prior to operation. In the presence of marked swelling the drug may be continued for some days after operation

3. Avoiding external pressure on the tissues covering the M-Sphere®.

Conformers, such as are used after simple enucleation, may compress the tissues and cause exposure of the M-Sphere®. *Conformers should never be used with any orbital implant.* Firm padding or pressure bandaging may also compress the tissues and cause exposure of the M-Sphere® and should be avoided. Instead a simple gauze eye pad should be held in place by adhesive tape.

Fitting of the artificial eye should be delayed for 3 to 6 months to allow for complete healing of the tissues and the complete organisation of the M-Sphere® by connective tissue.

Surgical instruments required

Eyelid speculum
Spring scissors (Wescotts)
Non-toothed Moorfield forceps
Fine-toothed forceps (St Martins)
Small locking needle holder
Squint (muscle) hooks x2
4.0 silk sutures with needles, x4 if single armed or x2 if double armed
5.0 Vicryl or silk suture x1
Fine artery forceps x4
Enucleation scissors
M-Sphere®
Cephalosporin / gentamycin solution for soaking M-Sphere®
Paraffin gauze
Rubber sleeve (Fashioned from the thumb of a sterile latex surgical glove)

Step One: Enucleating the eye

You will be using the four rectus muscles, anterior Tenon's tissue and conjunctiva to cover the anterior surface of the M-Sphere®. Your aim is to identify and avoid damage to these tissues while at the same time keeping them in their relative positions as you remove the eye.

General anaesthetic is preferred. Remember to handle the tissues gently to minimise swelling. If there is a lot of swelling, administer non-steroidal anti-inflammatory agents and postpone the operation for a few days to allow the swelling to subside.

Insert a speculum between the eyelids. Take a non-toothed Moorfields forceps and spring scissors and incise round the limbus. Lift and retract from Tenon's tissue off the globe. Locate the insertions of the rectus muscles. Mark each rectus muscle with a 4.0 silk suture tied firmly to one margin of the tendon. This prevents loss of the muscle and later makes it easy to open Tenon's space for insertion of the M-Sphere®. Cut off each rectus muscle at the globe. Exert gentle traction on each of the rectus muscles and clip the sutures to the drapes (Fig. 1.1).

Grasp the globe with a toothed forceps. Pull it forward and downwards. Slide a pair of curved scissors into the upper nasal quadrant beneath Tenon's capsule. After checking that Tenon's tissue is out of the way, cut the stretched optic nerve.

Continue the traction on the globe and cut the attachments of the superior and inferior oblique muscles. Remove the eye and place it on a sterile surface. Plug the socket with a gauze swab and leave the swab there to arrest bleeding while you prepare the M-Sphere®.

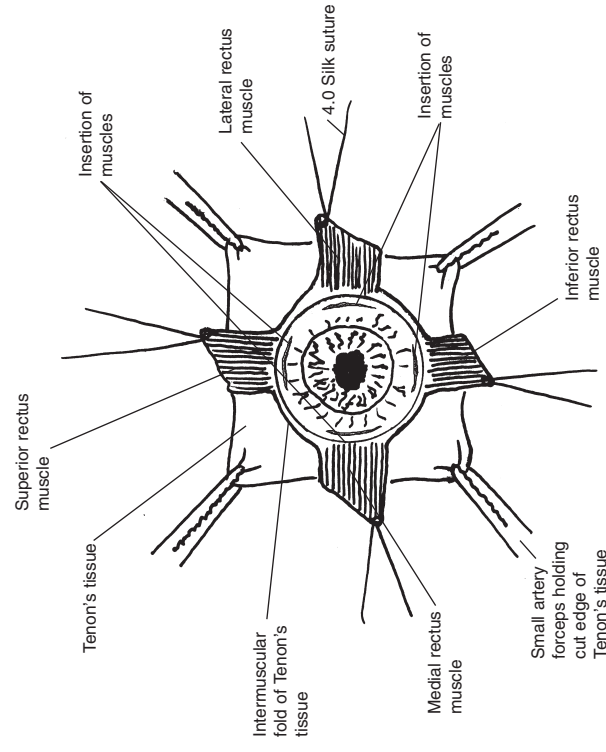


Fig. 1.1 Placement of the sutures before removal of the eye

Step Two: Selecting the correct size M-Sphere®

Your aim is to select the size of M-Sphere® which is large enough to fill the socket and eliminate dead space, yet not so large that it cannot be easily covered by the tissues.

M-Sphere® is supplied in spheres of 16mm, 18mm, 20mm and 22mm diameter. The spherical shape is suitable where facilities exist for moulding the socket and customising the artificial eye. (In other situations see shaping the M-Sphere® - Pg5)

The correct size M-Sphere® is about three-quarters the diameter of the eye that has been removed. However, if there are complicating factors such as poor blood supply or badly damaged tissues, a somewhat smaller than usual M-Sphere® should be selected.

For example, an eye 24mm in diameter has been enucleated. Normally a 20mm M-Sphere® would be considered. However, if the tissues are badly damaged or the patient is old, has vascular disease or there are other factors limiting the vitality of the tissues, or 18mm M-Sphere® should be used.

Another example might be: An eye 25mm in diameter is enucleated. $25 \times \frac{3}{4} = 18.75$ or about 19mm. Which size should be chosen? If the tissues are healthy a 22mm M-Sphere® could be used. If the vitality of the tissues is reduced a 20mm would be suitable.

Step Three: Preparing the M-Sphere®

Your aim is to prevent infection by soaking the M-Sphere® in an antibiotic solution. You may also need to shape the M-Sphere® to fit the patient's socket or to accommodate an artificial eye.

Soak the M-Sphere® for 1 to 2 minutes in an antibiotic solution such as cephalosporin 500mg with gentamycin 80mg made up as for parenteral injection (other antibiotics or normal saline may be used). The M-Sphere® will absorb the antibiotics and release them slowly into the tissues over several days.

Shaping the M-Sphere®.

Where facilities for manufacturing artificial eyes are not available and a stock prosthesis must be used, the anterior surface of the M-Sphere® sphere should be flattened to accommodate the thicker prosthesis. To do this, first soak the M-Sphere® for 2 or 3 minutes as above. This softens the M-Sphere® sufficiently for it to be shaped with a pair of heavy scissors (Fig. 3.1).

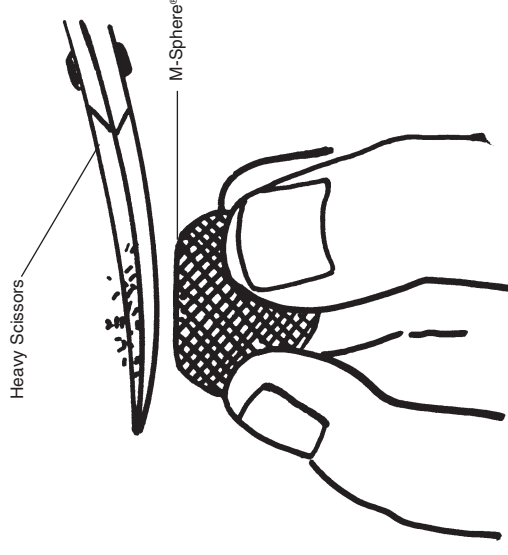


Fig. 3.1 Shaping of the M-Sphere® with a pair of heavy scissors to fit a stock prosthesis

Step Four: Inserting the prepared M-Sphere® into Tenon's space

Your aim is to place the M-Sphere®, deep into Tenon's space. This will ensure that there is sufficient Tenon's tissue and conjunctiva to cover the implant without having to stretch them. Avoiding stretch prevents internal pressure on the overlying tissues which could result in exposure of the implant.

Note: The tissues tend to stick firmly on contact with the M-Sphere®. This makes it difficult to adjust the position of the M-Sphere® after it has been placed in the orbit. This difficulty is overcome by using the thumb of a sterile latex surgical glove to cover the M-Sphere® while it is being positioned in the orbit.

Cut the thumb off a latex surgical glove and remove the tip to make a short, tapered rubber sleeve (Fig. 4.1).

Moisten the sleeve with saline and push the prepared M-Sphere® down into the bottom of the sleeve. The M-Sphere® should not protrude beyond the rubber at this stage (Fig. 4.2). If the anterior surface of the M-Sphere® has been flattened to accommodate a stock prosthesis care should be taken to make sure the surface is correctly orientated.

Remove the gauze swab from the socket. To open and expose the posterior part of Tenon's space pull on the sutures holding the four rectus muscles and reattach them to the drapes. Use four small artery forceps to grasp the edge of Tenon's capsule between the rectus muscles and pull it forward to maximise exposure of the interior of Tenon's capsule (Fig. 4.3).

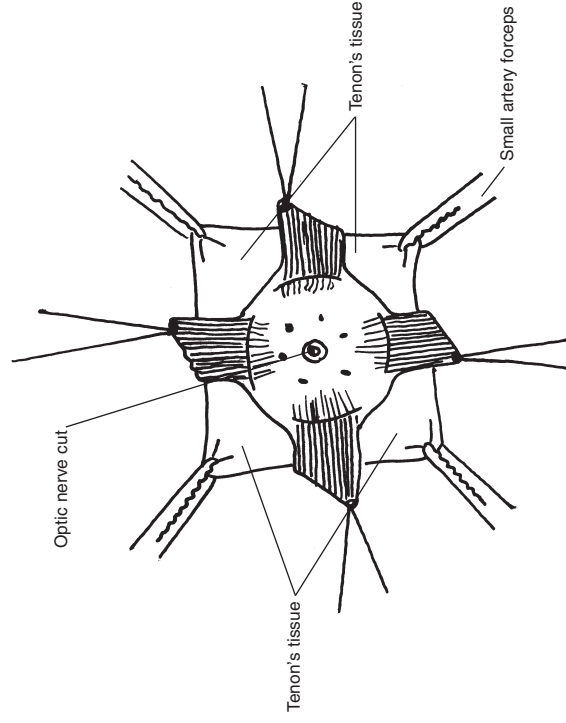


Fig. 4.1 Traction on sutures to expose Tenon's space for insertion of the M-Sphere®

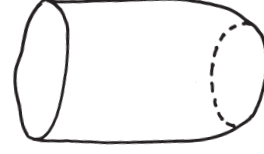

Fig. 4.2 Rubber sleeve cut from the thumb of a surgical glove

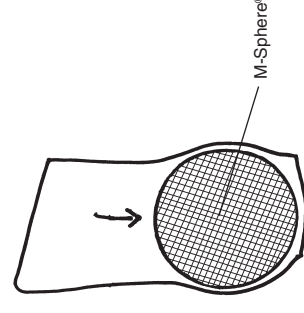


Fig. 4.3 M-Sphere® correctly placed in rubber sleeve

Step Four: Inserting the prepared M-Sphere® into Tenon's space (Continued...)

While maintaining traction on the four muscles and on Tenon's capsule, slide the rubber-covered M-Sphere® as far back into Tenon's space as possible (Fig. 4.4). Then put a finger into the rubber sleeve and, pressing firmly on the M-Sphere®, ease the rubber sleeve forward off the M-Sphere® (Fig. 4.5).

The posterior tissues will be drawn forward, adhere to the porous surface of the M-Sphere® and hold it in position deep in the orbit. The anterior tissues will lie loosely over the implant (Fig. 4.6).

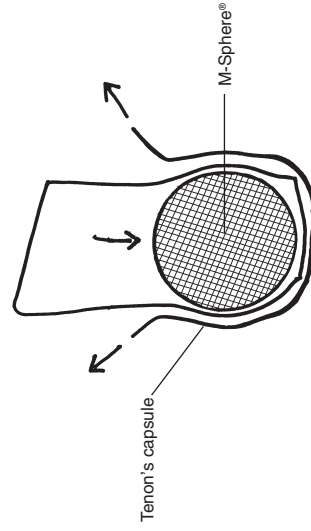


Fig. 4.4 M-Sphere® protected by rubber sleeve inserted into Tenon's space

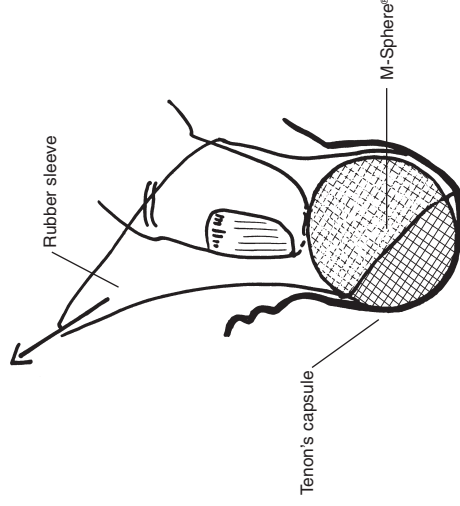


Fig. 4.5 Removal of the rubber sleeve while pressing the M-Sphere® deep into the orbit

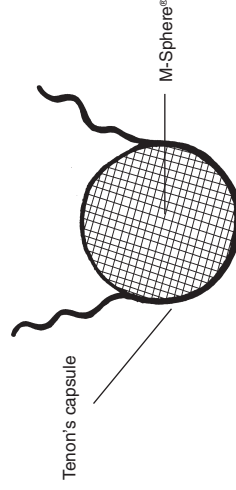


Fig. 4.6 M-Sphere® held in position by posterior Tenon's tissue

Step Five: Attachment of the rectus muscles.

Your aim is to attach the rectus muscles to each other so as to form an even sheet of well vascularised muscular tissue covering the M-Sphere®. Care should be taken to ensure that the rectus muscles maintain their positions so that the artificial eye moves naturally.

Find the tendons of the superior rectus and inferior rectus muscles. With the 4.0 silk sutures* already attached to the tendons, suture them together end to end over the front of the M-Sphere® spreading the muscles out as widely as possible. The joined ends should lie centrally (Fig. 5.1).

Find the suture holding the medial rectus muscle. Grasp the muscle with a Moorfields forceps and pull it laterally to expose the medial check ligament. Use a pair of spring scissors to free the medial check ligament from the rectus muscle. (Leaving this ligament in place may limit the range of movement of the M-Sphere®.) Spread the muscle to its full width and suture the free end to the medial edge of the joined superior and inferior rectus muscles using two or three interrupted sutures of 4.0 silk (Fig. 5.2).

Now find the suture holding the lateral rectus muscle and free the lateral check ligament as described above. Spread the muscle to its full width and suture the free end to the lateral edge of the joined superior and inferior rectus muscles with two or three interrupted sutures of 4.0 silk (Fig. 5.2)

* Note: Silk is used in this situation rather than Vicryl or Dexon. This is because it is important that the sutures should hold until the tissues are completely healed. In this situation Vicryl and Dexon sometimes break down too soon and should therefore be avoided.

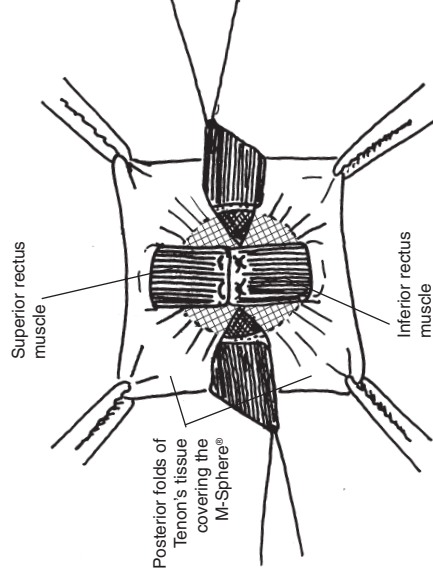


Fig. 5.1 Tendons of the superior and inferior rectus muscles sutured over the M-Sphere®

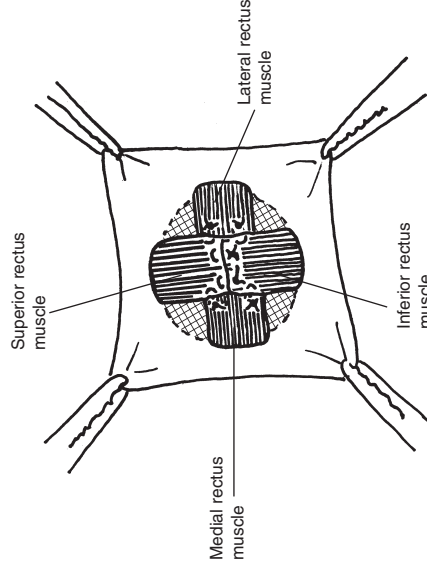


Fig. 5.2 Tendons of the medial and lateral rectus muscles sutured to the margins of the joined superior and inferior rectus muscles

Step Six: Closure of Tenon's tissue and conjunctiva

Your aim is to ensure that the M-Sphere® is completely covered by a layer of well vascularised connective tissue. This tissue must be very carefully sutured so as to cover the M-Sphere® without undue tension.

In most cases there will be plenty of tissue available to cover the M-Sphere®. If the tissue cannot be closed without undue tension make relieving incisions through Tenon's tissue behind the point of reflection of the superior fornix (Fig. 6.1).

Close the anterior portion of Tenon's capsule in a horizontal direction using several interrupted sutures of silk cutting these off close to the knots (Fig. 6.2).

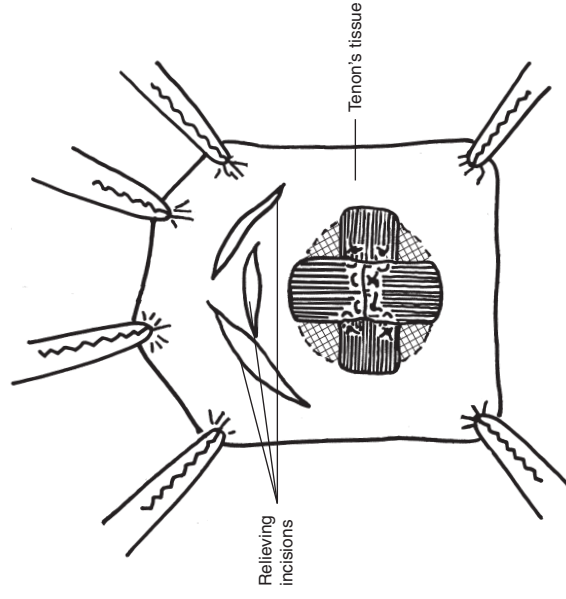


Fig. 6.1 Position of the relieving incisions where necessary to reduce tension in the tissue covering the M-Sphere®

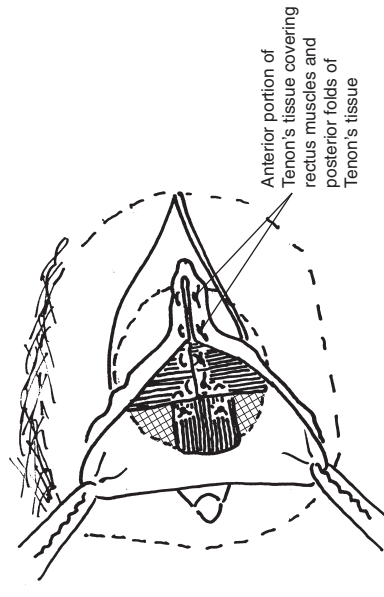


Fig. 6.2 Horizontal closure of the anterior cut-edge of Tenon's tissue using interrupted mattress sutures of 4,0 silk

Step Six: Closure of Tenon's tissue and conjunctiva (Continued)

Carefully check this suture line for complete closure and place additional sutures as necessary before closing the conjunctiva (Fig. 6.3).

Closure of the conjunctiva

The conjunctiva should be closed with a continuous suture of 5.0 Vicryl or equivalent absorbable material (Fig. 6.4).

At the end of the operation a small piece of Vaseline (or Paraffin) gauze is tucked into the lateral and inferior fornix, this serves to maintain it's depth in the first three or four days after operation. Pad the eye lightly and give antibiotic drops until the conjunctival wound is completely healed. If marked tissue swelling occurs give a non-steroidal anti-inflammatory agent (with the usual precautions) until the swelling is relieved.

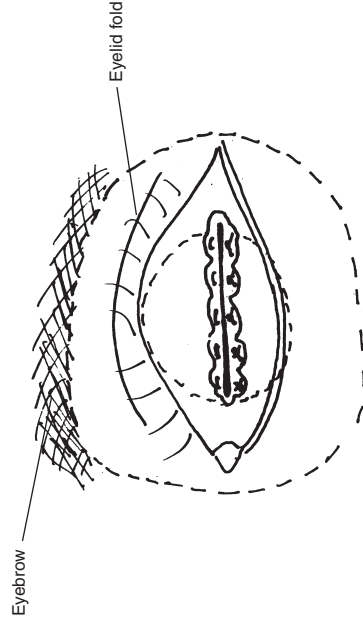


Fig. 6.3 Anterior closure of Tenon's tissue complete

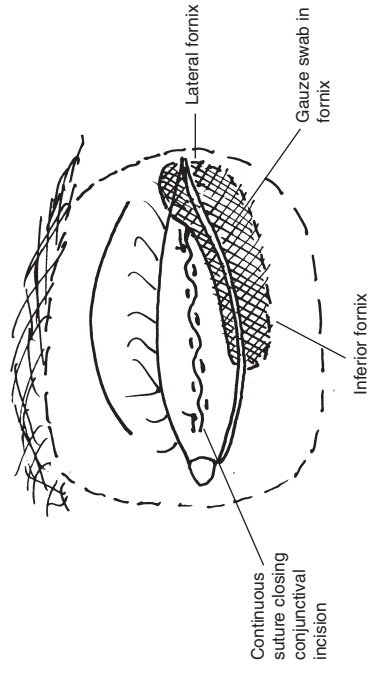


Fig. 6.4 Closure of conjunctiva showing position of vaseline gauze swab to maintain the fornix

Postoperative Care

Your aim is to maintain a good blood supply to the tissues covering the M-Sphere®.

Avoid over-packing the socket, firm padding, pressure bandaging or the use of a conformer as these may cause pressure necrosis of Tenon's tissue and conjunctiva where they press on the rigid M-Sphere®.

Managing Post-operative Complications

Complications that arise after inserting an orbital implant are most often due to internal or external pressure. Internal pressure from the swelling of traumatised tissues or the selection of too large an implant may result in exposure of the implant. External pressure applied to the eye after surgery, such as the use of a conformer or over firm bandaging, may cause ischemic necrosis of the tissues covering the implant and should be avoided.

Breakdown of the overlying tissues with exposure of the sclera or M-Sphere®

Treat promptly to avoid infection. Remove any exposed M-Sphere® using a dental drill. Then close the defect using local Tenon's tissue.

Exposed suture ends

These should be removed to prevent access of infection to the M-Sphere® which remains susceptible to infection until such time as it is fully incorporated into the host tissue.

Fitting an artificial eye

The fitting of an artificial eye should be delayed for at least three months to be sure that the overlying tissues is completely healed. By this time the M-Sphere® should be organised by host connective tissue. In certain circumstances, such as when the patient is old or ill, healing may be markedly delayed and fitting of an artificial eye should be postponed until slit-lamp examination shows that the overlying tissues is completely healed.

Surgical steps summarised

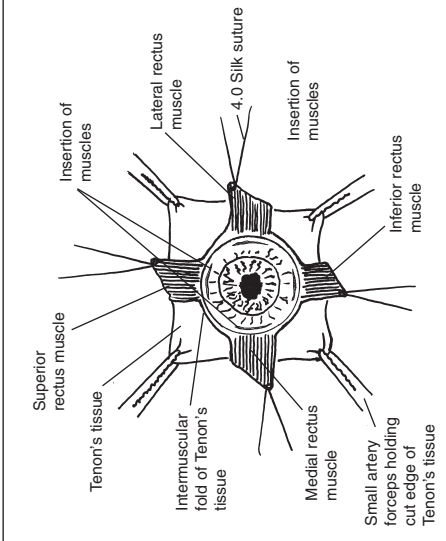


Fig. 1.1 Placement of the sutures before removal of the eye

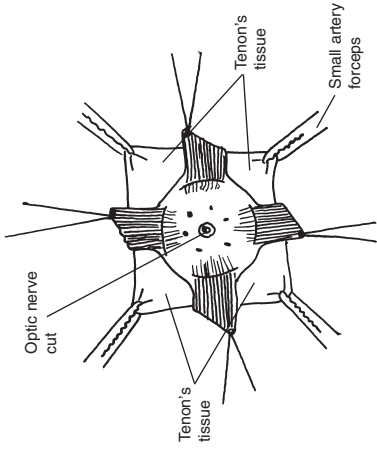


Fig. 4.1 Traction on sutures to expose Tenon's space for insertion of the M-Sphere®

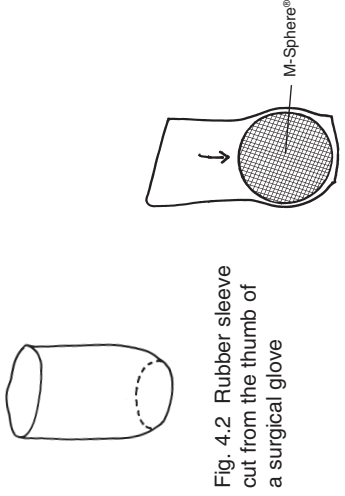


Fig. 4.2 Rubber sleeve cut from the thumb of a surgical glove

Fig. 4.3 M-Sphere® correctly placed in rubber sleeve

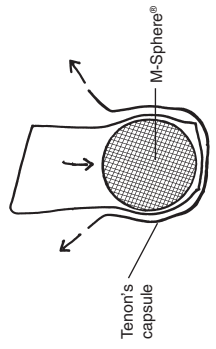


Fig. 4.4 M-Sphere® protected by rubber sleeve inserted into Tenon's space

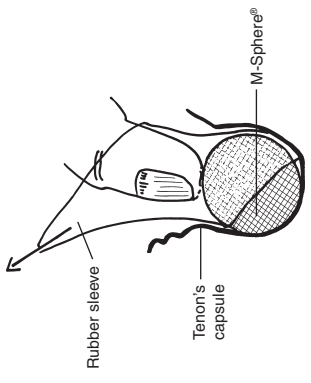


Fig. 4.5 Removal of the rubber sleeve while pressing the M-Sphere® deep into the orbit

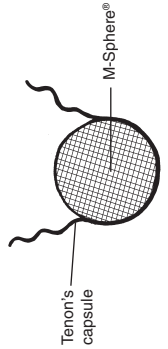


Fig. 4.6 M-Sphere® held in position by posterior Tenon's tissue

Surgical steps summarised

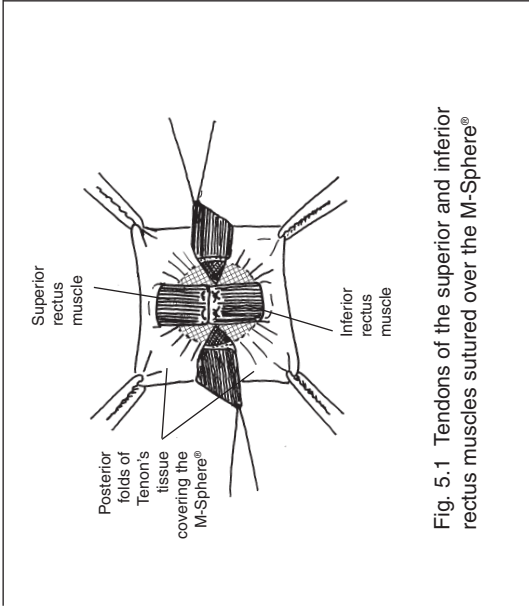


Fig. 5.1 Tendons of the superior and inferior rectus muscles sutured over the M-Sphere®

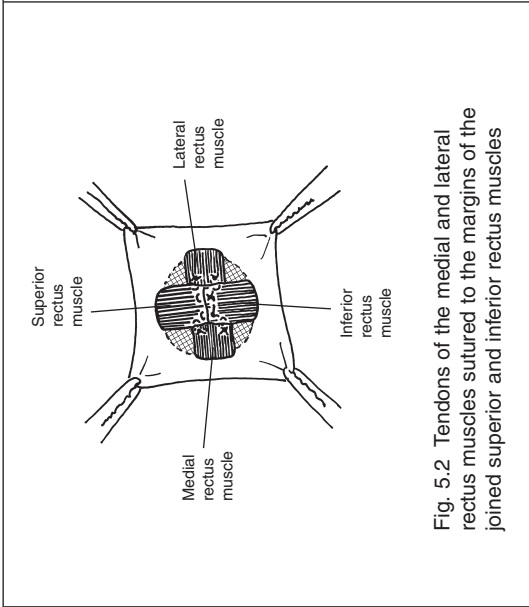


Fig. 5.2 Tendons of the medial and lateral rectus muscles sutured to the margins of the joined superior and inferior rectus muscles

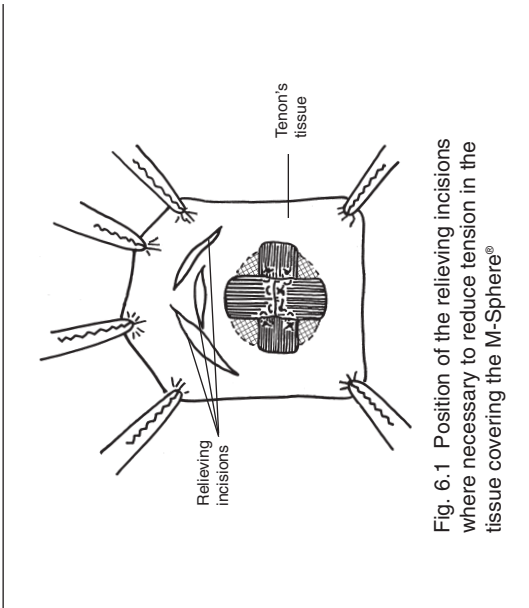


Fig. 6.1 Position of the relieving incisions where necessary to reduce tension in the tissue covering the M-Sphere®

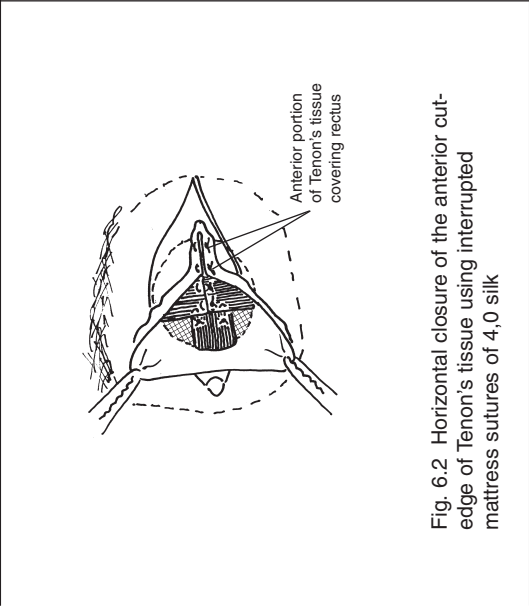


Fig. 6.2 Horizontal closure of the anterior cut-edge of Tenon's tissue using interrupted mattress sutures of 4,0 silk

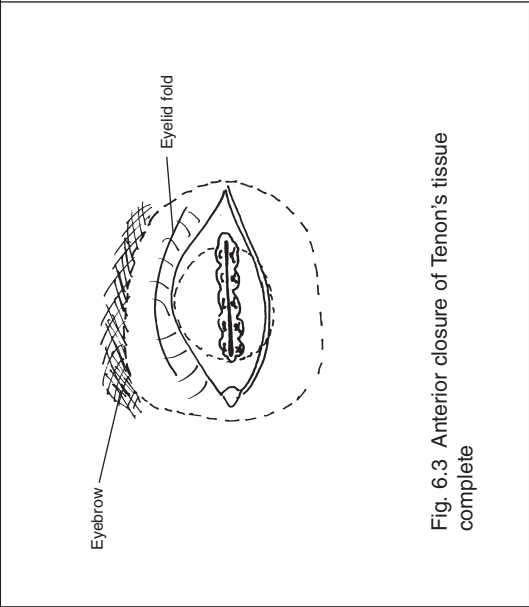


Fig. 6.3 Anterior closure of Tenon's tissue complete

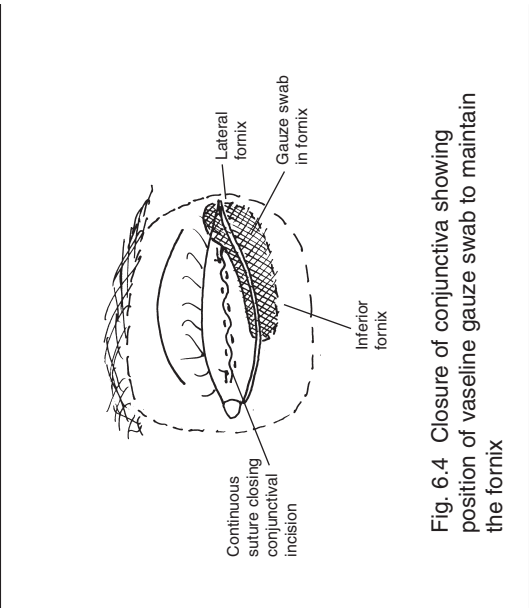


Fig. 6.4 Closure of conjunctiva showing position of vaseline gauze swab to maintain the fornix

MOLTENO® and MOLTENO Implant®, M-Sphere® and MoadBone® are registered trade marks of Anthony C. B. Molteno, FRCS, FRACO

References

- Allen, T. D., *Guist's bone spheres*. AM J. Ophthalmol Vol 13, pp226, 1930.
- McCoy, L. L., *Guist's bone spheres*. AM J. Ophthalmol Vol 15, pp960, 1932.
- Molteno, A.C.B., Van Rensberg, B., Van Rooyen, B., Ancker, E., "Physiological" *orbital implant*. Brit. J. Ophthal. Vol 57, pp615-621, 1973.
- Molteno, A.C.B., *Antigen-free Cancellous Bone Implants After Removal of an Eye*. Trans Ophthal. Soc. N.Z. Vol 32, pp36-39, 1983.
- Molteno, A.C.B., Elder, M.J., *Bone Implants After Enucleation*. Australian and New Zealand Journal of Ophthalmology Vol 19(2), pp129-136, 1991.
- Jordan DR, Huang I, Browstein S, McEachren T, Gilbert S, Gravhovac S, Mawn L, *The Molteno M-Sphere*. Ophthalmic Plastic and Reconstructive Surgery, Vol 16(5), pp356-62, 2000.

Notes

Notes



MOLTENO[®]
OPHTHALMIC LIMITED

P. O. BOX 6322 • DUNEDIN • NEW ZEALAND
TEL ++64 (0)3 479 2744 • FAX ++64 (0)3 479 2444
EMAIL molteno@clear.net.nz • WEBSITE www.molteno.com

*MOLTENO[®] and Molteno Implant[®], M.Sphere[®] and MoaBone[®] are registered trade marks of
Anthony C. B. Molteno, FRCS, FRACO*

U.S. Patent Nos. 4,457,757 4,750,901